

SAMPLE

New Concept in Splint Design and the Treatment of Tension Headache, Cervicalgia, and Facial Pain



Dale W. Greer, DDS
Private Practice
Dallas, Texas
Phone: 972.233.4546
Email: dalegreer@sbcglobal.net



Mike Neeley, DDS
Private Practice
Dallas, Texas
Phone: 214.521.3148
Email: mikeneeley@hotmail.com

The case presented in this article describes a new concept for the construction of a splint used in the relief of pain symptoms of headache and its usefulness in the completion of the case to final definitive restorations.

This new concept takes into consideration a rapid method of obtaining a very comfortable bite for splint construction. In addition to this the uniqueness of the splint material made with this bite registration results in more rapid transition to definitive restorations and the stabilization of occlusion. The key element for this to occur is done by the rapid relaxation of the oral facial musculature complex before recording the proper centric relation occlusal (CRO) bite registration.

Research demonstrates that about two thirds of patients with temporomandibular joint (TMJ) dysfunction/headaches, experience adequate long-term relief with most any kind or design of splint therapy.^{1,2}

Many patients have benefited from the relief of facial pain and headaches with the use of these appliances. These types of appliances include:

- Anterior deprogrammer (Lucia jig, NTI-SS, Inc)
- Full coverage acrylic splints (Tanner, Gelb, CRO splints)
- Anterior repositioning splints

All of these appliances have been proven to be effective for treating head and neck pain.

Nevertheless drawbacks have been associated with each type of design.

For example, anterior deprogrammers do not provide any posterior occlusal support and may overload the TMJ. This can drastically alter the patient's occlusion.^{3,4}

Full coverage splints are time consuming to deliver and adjust. In addition, new bruxism patterns can develop over time because of hard plastic, occlusal surface. It has been suggested that full coverage splints immobilize the maxillary sutures which are intended to be movable.⁵

This appliance eliminates proprioceptive, accommodative responses from the muscles and periodontal ligament connection.

Lastly, anterior repositioning splints can be uncomfortable to wear and require 24-hour usage which is sometimes unacceptable to the patient.

The answer may be in a new approach to the fabrication of the splint that incorporates muscle relaxation in a nonrigid material needed to mimic the natural functional dentition.

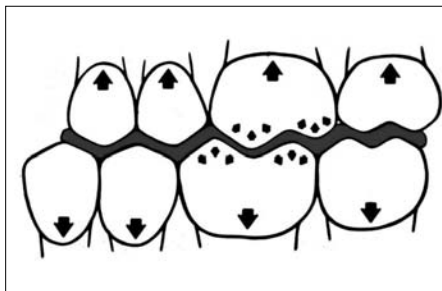


Figure 1—Aqualizer decreased proprioceptive responses.

Finding a Functionally Generated Balanced Occlusal Splint

The functionally-generated, balanced, occlusal splint has been designed and used for almost 30 years. The Aqualizer (Jumar Corporation) is a hydrodynamic equalizing orthotic for the neuromuscular, skeletal, proprioceptive systems of the mouth and cranium (Figures 1 and 2). According to Pascal's Law of Hydrodynamic Equalization, it achieves what no other appliance can achieve by creating a new physiologic alternative to arbitrary clinical-

directed mandibular placement, for centric relation (CR)/centric occlusion (CO) that is a functionally muscle-directed position.⁶ The Aqualizer is highly valuable when used as a diagnostic device to determine if the patient's head and neck pain have dental origins. The limitation with this appliance is its durability because it is considered dispensable; most pa-

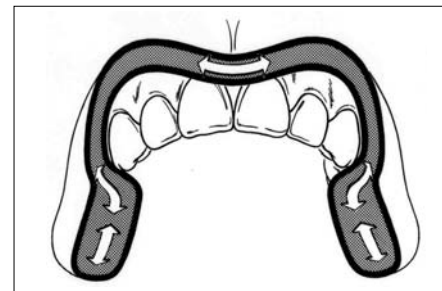


Figure 2—Hydrodynamic equalizing effect for mandibular balancing.

tients can wear it only for 3 to 14 days and is rendered ineffective because of the limitations of the material from which it is made.

This flaw begs the need for a permanent, durable, comfortable appliance that mimics the functional orthopedic concept of the Aqualizer. The new Neeley appliance, developed by the co-author, was created to fulfill this need and provide what no other permanent occlusal splint can achieve. It is very effective for relaxing the musculature of the head and neck region by balancing the mandible as it articulates with the cranium.⁷

The Neeley Appliance

The proposed benefits of the Neeley appliance include: comfortable, neuromuscular balance; skeletal balance; functionally generated; fewer adjustments; and flexibility to allow sutural movement of the 26 cranial bones. Initial findings show that flexibility and forgiveness of the material will remove unwanted, repetitive, compressive forces to the maxillae and the cranium because of imbalances in the patient's occlusal scheme. This appliance eliminates proprioceptive, accommodative responses from the muscles and periodontal ligament connection.⁶ Also, it permits freedom of the muscles to find the most functionally generated, comfortable position while providing posterior occlusal support to maintain healthy joint loading unlike an anterior deprogrammer. It is not a clinician-directed positioning of the mandible but a musculoskeletal dic-

Case Study

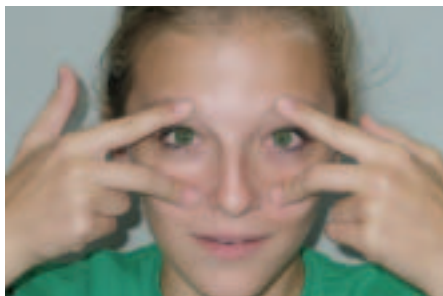

Figure 3—Patient's epicenters of facial pain.

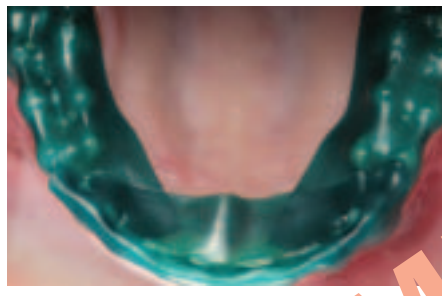


Figure 4—Occlusal wax bite displaying heavy anterior contact.

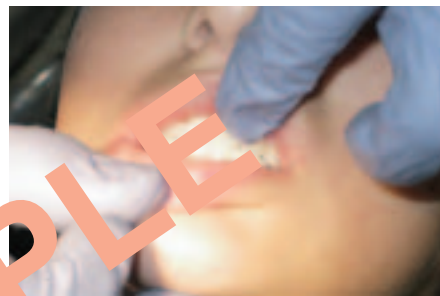

Figure 5—Palpating for fremitus forces.

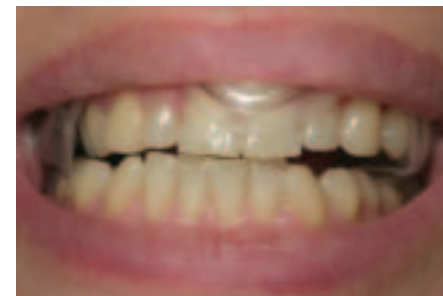

Figure 6—Aqualizer in place for 8 minutes.

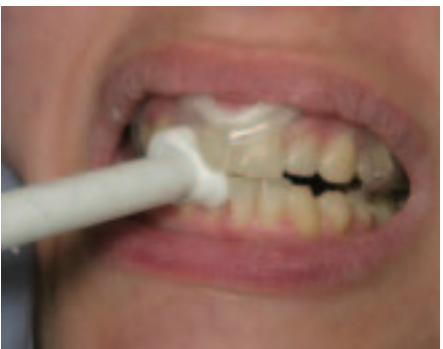

Figure 7—Anterior portion of bite registration taken.

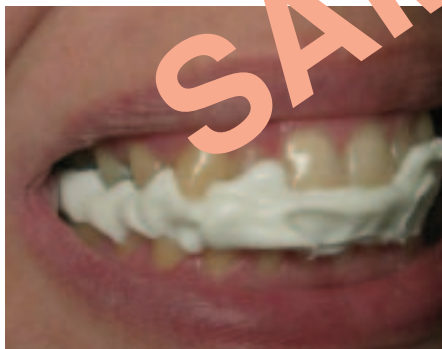

Figure 8—Posterior area of bite taken with Mousse while the anterior section in place.

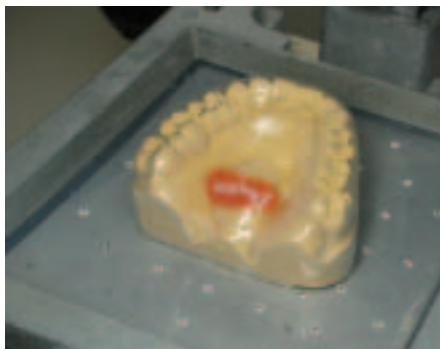


Figure 9—Ethyl-vinyl material vacuum formed.

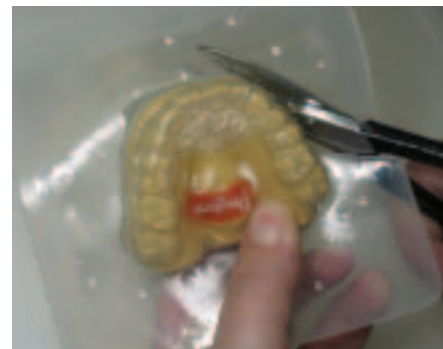


Figure 10—Cut out splint template.

tated position, it is functional generated. This allows the patient to find his/her most comfortable position or posture of the mandible, and the occlusion is designed to match this position.⁸

Case Study

A 17-year-old patient visited the office with a complaint of tension headaches and facial pain that had lasted for more than 10 years. When the patient was asked where the pain was located she pointed to the area with her fingers (Figure 3). Her family and the patient had visited numerous physicians to seek help for her condition. The young woman received many professional opinions and had tried several treatments and medications, but without a resolution to her complaint. At age 12 and 15, she had magnetic resonance imaging (MRI) and computerized axial tomography (CAT) scans which proved nonremarkable, but ruled out the primary catastrophic causes of headache such as tumor or aneurysm. Thereafter, a pediatric neurologist diagnosed her with "chronic daily headache" symptoms. When the patient was asked to quantify her headache and facial pain on a scale of 0 to 10, she rated it between 4 and 7. Several different antidepressants and selective serotonin reuptake inhibitors had been prescribed to her with only limited success. Injections of Botox for

headache relief was successful but only lasted for 2 months. Because of cost, the family decided not to continue the Botox treatment and began to lose hope for their daughter.

Upon examination of the patient's occlusion it was found that her first contact in CR was on Teeth Nos. 8 and 9, and her CO contact on Teeth Nos. 7 through 10 only (Figure 4). Also, fremitus was noted on all upper incisors (Figure 5). This occlusal scheme provided no posterior occlusal support of the TMJ. Fortunately, both joints were in excellent condition and without symptoms. Her range of motion at the incisal edge position was 49 mm, and pain was not present upon palpation of the lateral or posterior joint areas. The patient's classification of occlusion was class I molar and cuspids.

Because of cost, the family decided not to continue the Botox treatment and began to lose hope for their daughter.

When the patient tapped her teeth together, the fremitus vibration in the anterior teeth was also felt with palpation over the nasal bones and the supraorbital notch

areas of the frontal bones. The dentists agreed it was not a coincidence that this was also the areas the patient had disclosed as the origin of her headaches. The goal was to provide the patient with a Neeley appliance worn all day (24 hours) to determine if she would be relieved of her symptoms.

Splint Construction

Using the bite registration, impressions were taken for upper and lower study models, and were poured, trimmed, and prepared for mounting which was taken only after the musculature was relaxed. Biavati has found that relaxation of the musculature is accomplished by inserting the Aqualizer for a minimum of 8 minutes⁹ (Figure 6). The patient was instructed to rest with the Aqualizer in place and to sip small amounts of water every 30 seconds. Using the Aqualizer to swallow would reprogram the musculature of the head and neck while diminishing the proprioceptive accommodative response of the muscles.⁹ Then, the bite registration was taken with the Aqualizer in place while light occlusal force was applied by the patient. Next, a Quick Set Mousse (Discus Dental, Inc) bite registration material was injected from cuspid to cuspid to record the position (Figure 7). The Aqualizer was removed after setting, and the posterior occlusion was registered with the anterior bite

registration in place (Figure 8), then was removed from the mouth and used to mount the case. The appliance was made from Pro-Form's 0.150-inch or 0.190-inch laminate (Dental Resource, Inc), and was durable, flexible, and adjustable. Lastly, the laminate sheet was heated and formed using a vacuum former machine (Figure 9), and the basic form was cut out using shearing scissors (Figure 10), which would be prepared before mounting the models.

The articulator of choice was a "plasterless" type, specifically the Galetti (Kerr Corporation) articulator (Figure 11), which would enable the operator to remount with ease when necessary. The models were secured to the upper and lower members, the bite registration was positioned between the models and the articulator's upper and lower members were secured (Figure 12). The registration was removed while observing the interocclusal distance from posterior to anterior keeping in mind that full articulation of the lower arch would occur with the appliance. Occasionally, a minor adjustment to the articulator was needed when decreasing the vertical dimension for proper seating into the laminate material (Figure 13).

The next step required high heat to stamp the occlusion. Then, the models need to be remounted and the appliance heated for approximately 45 seconds with a



Figure 11—Galetti articulator.



Figure 12—Models mounted with functionally generated bite.

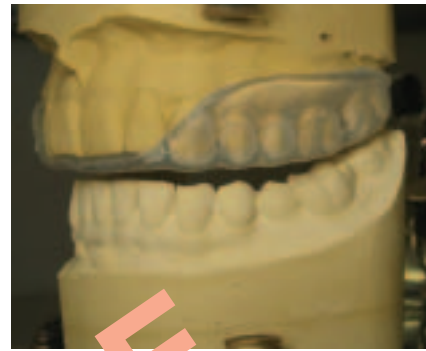

Figure 13—Occlusion on appliance before stamping the occlusion.



Figure 14—Heating the appliance before stamping the occlusion.

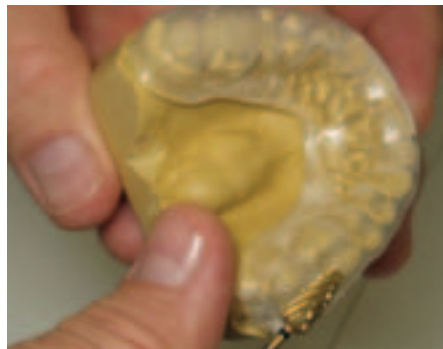

Figure 15—Gross reduction of stamped occlusion.



Figure 16—Polishing the appliance surface.

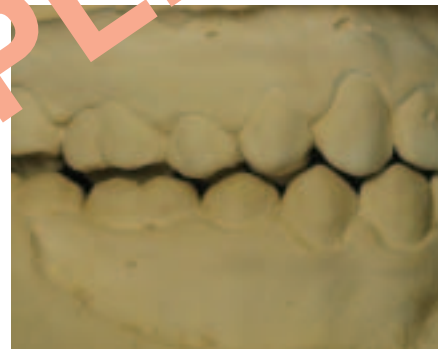


Figure 17—Study models mounted.

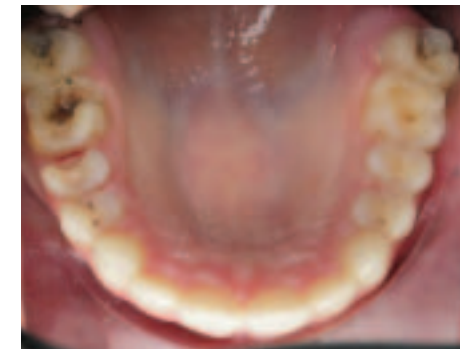

Figure 18—Occlusal view of preparations.

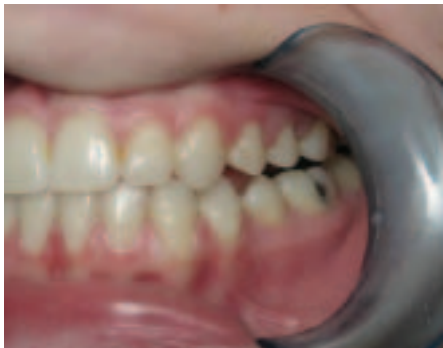

Figure 19—Lateral view of preparations.

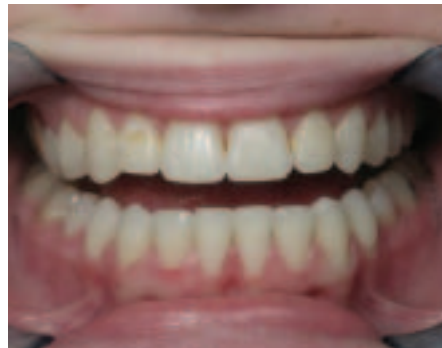

Figure 20—Frontal view of seated onlays.

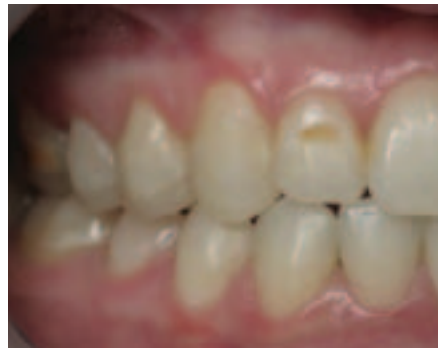

Figure 21—Lateral view of seated onlays.

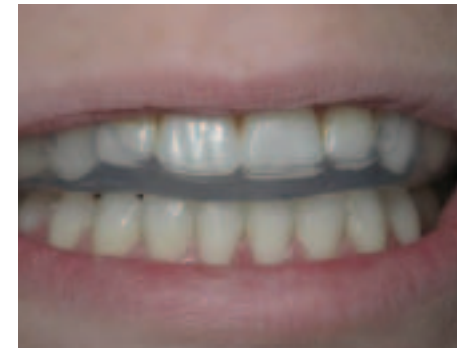

Figure 22—Neeley appliance for nighttime wear.

paint-stripping gun (super hot blow dryer), found at your local hardware store (Figure 14). Next, petroleum jelly was applied to the opposing model and the articulator closed to “stamp” the occlusion. After the material cooled, the occlusion was adjusted as one would for a traditional full coverage CR/CO acrylic splint with mutually protected occlusion. A No. 4505 gross reduction acrylic bur (EOP, Inc) was used and all areas of occlusal excess except the cusp tip marks (Figure 15) were removed. Then, the anterior segment was smoothed out leaving a 15° incline for discluding the posterior teeth in excursions.¹⁰ Finally, the soft material with a coarse No. 21813 Acrylic/ Composite polisher (EOP, Inc) was smoothed (Figure 16) and a Robinson wheel (EOP, Inc) to remove any leftover rubber tags was used.

Delivery

At the beginning of the delivery appointment the Aqualizer was

inserted. The patient continued to wear the Aqualizer for 8 minutes while swallowing every 30 seconds to gain relaxation of the muscles. The Neeley appliance was inserted to determine if the upper teeth fit and was modified as needed. Next, the occlusal function/fit was checked as the opposing arch occludes with the appliance. The AccuFilm articulating paper (Parkell, Inc) was used and coated with an ultrathin film of petroleum jelly to mark and adjust the bite with a No. 21813 Acrylic/ Composite Polisher. The patient had all her opposing teeth in contact with the appliance. The goal was to establish full arch contact in CO, and it was important that the patient made simultaneous bilateral contact with the appliance while lightly self-testing the first contact point.

The patient was instructed to wear the appliance for 24 hours per day except when eating, and was given care instructions and asked to return to the office in 1 week. After 1 week the patient reported having

just 1 headache which was at a pain level of 3. The patient was ecstatic about the possibilities. She continued to wear the appliance for an additional 3 weeks without 1 headache. During this time period it was appropriate to develop the treatment plan sequence because the authors knew her occlusion was a major contributor to her headaches.

Occasionally, practitioners should retool and rethink procedures that have been used for many years.

Treatment Plan

The first step was to create posterior stops which would support the occlusion and reduce the percussive pressure on the anterior teeth. Next, the models were

mounted in CR (Figure 17). The plan was to apply direct composite to the occlusal surface of the upper molars creating a “lift” of the occlusion so the patient would not have to wear the appliance during the daytime. Presuming success, the plan was to balance her occlusion by fabricating permanent porcelain onlays on all of the upper posterior teeth.

Restorative Treatment

The composite provisional “lifts” were effective but required 2 additional selective equilibrations. After 6 months of positive results, the patient chose to proceed with permanent porcelain restorations. Pressed porcelain was the material of choice for strength and esthetics. The patient was appointed to receive occlusal onlay preparation on all upper molars and bicuspids. Injections were given and the patient’s teeth were prepared (Figures 18 and 19). Impressions were created using polyvinylsiloxane

material (First Half, Danville Materials). The bite registration was taken with Vanilla Mousse (Discus Dental, Inc) in the patient's CR position. A temporary inlay/onlay material was used to protect the exposed dentin areas. Next, a thin splint was fabricated provisionally as a 24-hour appliance. The ceramist was prescheduled to build the case which would be ready to deliver in 1 week. All the onlays were tried on for fit, contacts and occlusion, and upon verification were seated using Variolink dual-cure cement (Ivoclar Vivadent, Inc) (Figures 20 and 21). Lastly, a Neeley appliance was fabricated for the patient to use for nighttime wear to protect the restoration and balance of the mandible (Figure 22).

mately 1 per month.

Conclusion

Occasionally, practitioners should retool and rethink procedures that have been used for many years. However, great improvements have been made when traditional beliefs are questioned. The Neeley appliance is a new concept in splint design although it uses some concepts of traditional splint therapy. Nevertheless, further study and research is needed to determine the long-term durability and success of the appliance. The Neeley's hallmarks are: the reproduction of the functionally generated, balanced, occlusal position using the Aqualizer; the flexible nature of the

found that their patients have been very pleased with the results of the Neeley appliance. Many patients have found relief of head, neck, and facial pain through occlusal and bruxism management. ■

References

1. Frumker SC, Kyle MA. The dentist's contribution to rehabilitation of cervical posture and function: orthopedic and neurological considerations in the treatment of craniomandibular disorders. *Basal Facts*. 1987;9(3):105-109.
2. Mann AW, Pankey LD. Concepts of occlusion: the PM philosophy of occlusal rehabilitation. *Dent Clin North Am*. 1963;6:21.
3. Spear F. Occlusion in the new millennium: the controversy continues. *Signature*. 2000;7(2):18-22.
4. Boyd JP. *NTI-SS User's Guide Book*. 2002;15.
5. Kois JC. Functional occlusion diagnosis and management. *Seminar Handout*. 1996;24.
6. Lerman MD. A revised view of the dynamics, physiology and treatment of occlusion: a new paradigm. *Cranio*. 2004;22(1):50-63.
7. Ehrlich R, Garlick D. The effect of jaw clenching on the electromyographic activity of 2 neck and 2 trunk muscles. *J Orofac Pain*. 1999;13(2):115-120.
8. Nuelle DG, Alpern MC. A new pathophysiology and classification of TMJ dysfunction. *TMJ Update*. 1988;6(1):11-14.
9. Biavati PS, Guida F. Neuromuscular re-equilibration of the stomatognathic system: the feedback system. *Gnathology Dept Dentistry Clinic of Genoa University. Unpublished research paper*. 2003.
10. Williamson EH, Jundquist DO. Anterior guidance: its effect on electromyographic activity of the temporal and masseter muscles. *J Prosthet Dent*. 1983;9(6):816-823.

Many patients have found relief of head, neck, and facial pain through occlusal and bruxism management.

The patient was examined twice for minor bite adjustments during the first 3 months of postdelivery. The patient has reported some minor tension headaches approxi-

ethyl-vinyl-laminate material in a permanent splint design; and it can overcome many of the shortcomings found in traditional appliances. Some practitioners have

Product References

Product: Aqualizer
Manufacturer: Jumar Corporation
Location: Prescott, Arizona
Phone: 800.435.7863
Web site: www.aqualizer.com

Product: Galetti Articulator
Manufacturer: Kerr Corporation
Location: Orange, California
Phone: 800.KERR.123
Web site: www.kerrdental.com

Products: Pro-Form 0.150-inch and 0.190-inch laminate
Manufacturer: Dental Resource, Inc
Location: Maple Lake, Minnesota
Phone: 800.328.1276
Web site: www.dentalresources.com

Products: No. 4505 Gross Reduction Acrylic Bur, No. 21813 Acrylic/Composite Polisher, Robinson Wheel
Manufacturer: EOP, Inc
Location: St. Paul, Minnesota
Phone: 800.328.8021
Web site: www.eopinc.com

Products: Quick Set Mousse Bite Registration Material, Vanilla Mousse
Manufacturer: Discus Dental, Inc
Location: Culver City, California
Phone: 800.422.9448
Web site: www.discusdental.com

Product: First Half
Manufacturer: Danville Materials
Location: San Ramon, California
Phone: 800.822.9294
Web site: www.danvillematerials.com

Product: AccuFilm articulating paper
Manufacturer: Parkell, Inc
Location: Farmingdale, New York
Phone: 800.243.7446
Web site: www.parkell.com

Product: Variolink dual-cure cement
Manufacturer: Ivoclar Vivadent, Inc
Location: Amherst, New York
Phone: 800.533.6825
Web site: www.ivoclarvivadent.us.com

Product: Lucia jig
Manufacturer: NTI-TSS, Inc
Location: Mishawaka, Indiana
Phone: 877.468.4877
Web site: www.NTI-TSS.com

SAMPLE